

1:55 pm – 2:07 pm  
**Sheldon S. Lin, MD**  
(Newark, NJ)

2/6/2015

**Hallux Valgus in presence of Metatarsus Adductus**

Sheldon S Lin, MD  
Assoc Professor  
Rutgers-The New Jersey Medical School

*linsheldon@aol.com*

**Metatarsus Adductus-characterized by medial deviation of forefoot**

- Other terms
- Metatarsus varus
- Metatarsus adductus et supinatus
- Metatarsus adductovarus

**Differential diagnosis: medial deviation of forefoot other than MA**

- Children
- Dynamic in-toeing
- Clubfoot or its residual deformity of forefoot
- Anomalous muscle with club foot
- Skewfoot
- Neuromuscle Causes
- Medial Deviation of neck of talus
- Trauma-loss of anterior and lateral compartment
- RA

**KEY Question?**

- For an adult, how does one address **hallux valgus and presence of metatarsus adductus?**


**Historical concept for growing child-adolescent**  
Herman-Merridan procedure  
-arsenocollateral capsulotomy

Start and associated later profiles shown at 14 yrs follow-up a 47% failure rate.  
Over half had painful dorsal prominences  
SAR had difficulty with shoes

Concept: best used for young 3-4 yr old and for only resistant cases

Hegman CH et al JMS-A, 1958 40: 299-312

Kendrick RE et al JBJS 1970 52:61-70



**Historical concept for growing child-adolescent**  
Multiple MT Osteotomy

Dorsal approach  
Transverse, dome shaped, ribbing wedge


Technical difficult to execute and judge where to position

Concept: Best used for young 5 yr old and for only resistant cases

Marschke DE et al J Foot Surg 1992 31:607

Marschke DE et al J Foot Surg 1986 25:66-64


Keylin: JCS et al Br J Surg 1966 53:558



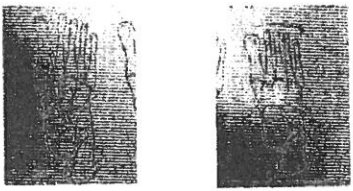
**Medial Column Lengthening  
Lateral Column Shortening**

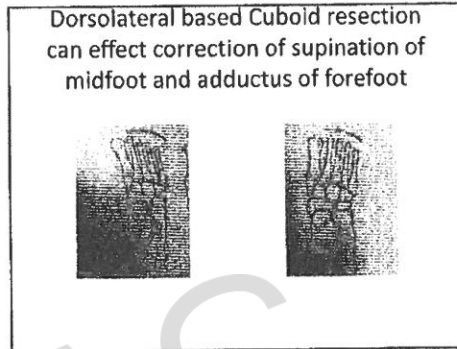

**Caution:**  
General Concept: Wedges of bone from longer column can be excised and placed into an osteotomy site of shorter column

Actual application via placing base of wedge more dorsal or plantar  
The combination of Fowler procedure, which is lowering medial column to correct metatarsal vault with dorsal capsulotomy restoring osteotomy of cuboid.



**Medial Column Lengthening  
Lateral Column Shortening**





AOFAAS  
2015

**Hallux Valgus:  
Other MT  
Osteotomy**

Other operations involving MT have been used alone and in combination with more classic operations at osteotomy.

- a. Proximal 1st MT osteotomy
- b. 1<sup>st</sup> MT-medial cuneiform fusion
- c. For growing child, partial proximal 1st MT epiphysodesis

